



THE COLLEGE OF
OPTOMETRISTS

Stage Two

Overarching case scenario 74

AGE AND GENDER Female aged 27 years

ETHNIC BACKGROUND Caucasian

OCCUPATION AND HOBBIES nurse, non-driver, crafting

PRESENTING SYMPTOMS AND HISTORY Frontal HAs most days – can occur any time. Started about 6 weeks ago. Vision seems less clear, also. Stressed at work – new job with more responsibilities. Thought symptoms were connected with new job, but seem to be getting worse rather than better.

GENERAL HEALTH AND MEDICATION Good. Citalopram. Is trying to lose weight as has been classed as obese.

POH/FOH Rx for DV tasks since teens/ grandmother AMD.

CURRENT Rx and VA R-1.25DS 6/12 L-0.75/-0.25x135 6/9-3

REFRACTION R -1.25/-0.25x55 6/9-3 PH worse L -1.00DS 6/9-3 PH worse

BINOCULAR STATUS Distance cover test NMD
Near moderate XOP good recovery

FIXATION DISPARITY NO SLIP, D&N

MOTILITY full, no pain or diplopia.

CONVERGENCE 12cm

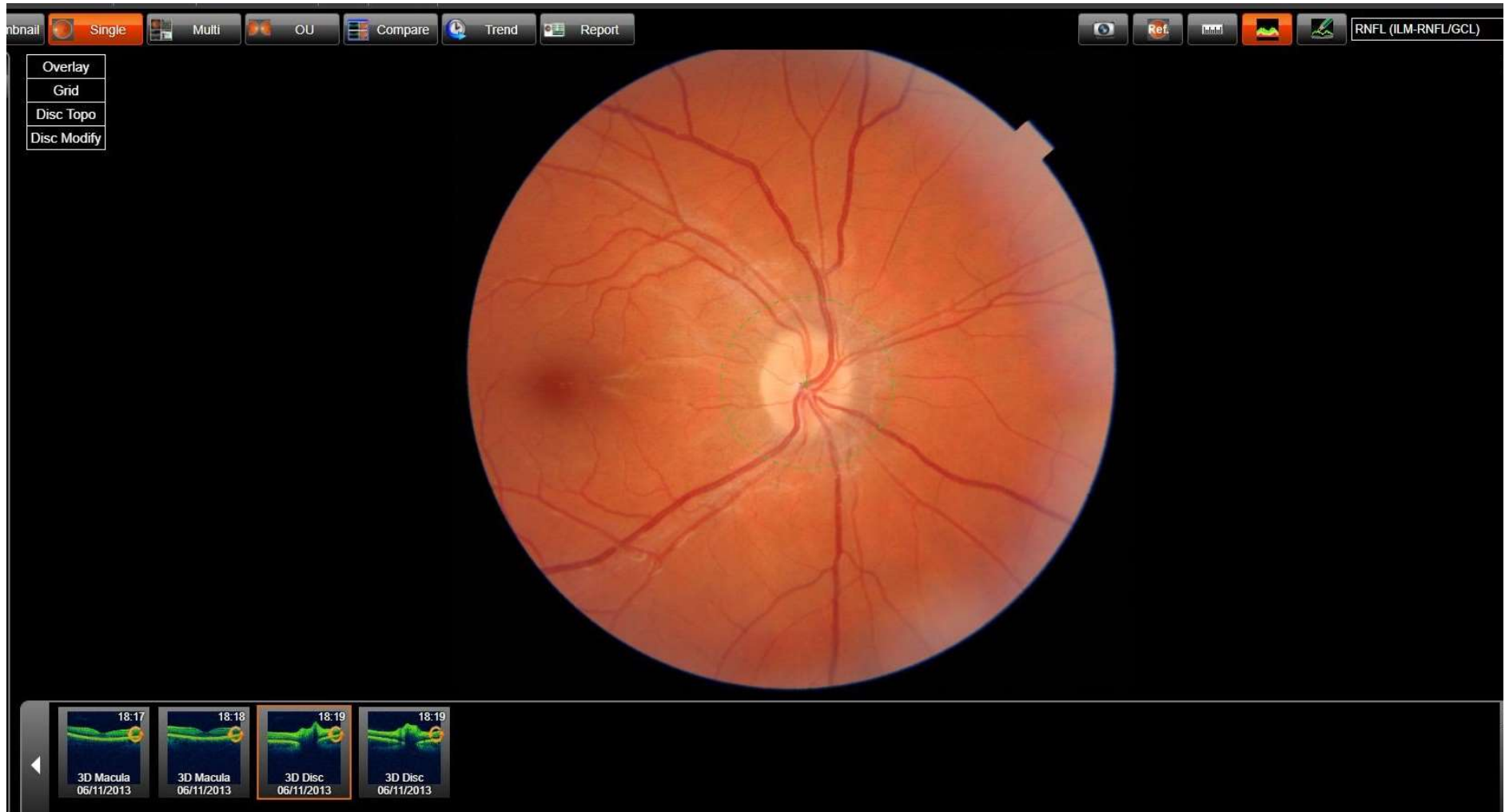
PUPIL REACTIONS sluggish response DCN, no RAPD

FUNDUS EXAMINATION see fundus photos

EXTERNAL EYE EXAMINATION normal

FIELDS Not carried out

Fundus Image RE



Fundus Image LE

